

## Zika vírus and neurological manifestation: a systematic review

Zika vírus e manifestações neurológicas: uma revisão sistemática

Zika vírus y manifestación neurológica: una revisión sistemática

### RESUMO

Objetivo: Determinar as principais manifestações neurológicas decorrentes da infecção humana pelo vírus Zika. Metodologia: Revisão sistemática de artigos publicados no Science Direct e Scielo, com o seguinte algoritmo de busca: Zika vírus e manifestações neurológicas e doenças do sistema nervoso. Estudos epidemiológicos relatando distúrbios neurológicos relacionados à infecção pelo zika vírus foram incluídos. Estudos em animais e revisões sistemáticas foram excluídos. Os dados foram extraídos e selecionados por 3 pesquisadores, que concordaram com os artigos selecionados. Resultados: Foram selecionados 26 artigos nesta revisão, que revelaram como principais alterações Síndrome de Guillain-Barré, Microcefalia, encefalite, meningoencefalite, mielite, paralisia facial, alterações congênitas, alterações oculares, além de alterações radiológicas e eletroencefalográficas. Conclusão: A infecção pelo vírus Zika causou uma série de alterações neurológicas na população infectada, entre adultos ou recém-nascidos. O acometimento mais frequente foi a síndrome de Guillain-Barré, sendo a microcefalia a mais grave decorrente de infecção no período pré-natal.

**DESCRITORES:** Zika vírus; Manifestações neurológicas, Doenças do sistema nervoso.

### ABSTRACT

Objective: To determine the main neurological manifestations resulting from human infection by the Zika virus. Methodology: Systematic review of articles published in Science Direct and Scielo, with the following search algorithm: Zika virus and neurological manifestations and diseases of the nervous system. Epidemiological studies reporting neurological disorders related to Zika virus infection were included. Animal studies and systematic reviews were excluded. Data was extracted and screened by 3 researchers, who agreed on the articles selected. Results: 26 articles were selected in this review, which revealed Guillain-Barré syndrome, microcephaly, encephalitis, meningoencephalitis, myelitis, facial paralysis, congenital alterations, ocular alterations, as well as radiological and electroencephalographic alterations as the main alterations. Conclusion: Zika virus infection has caused a series of neurological alterations in the infected population, whether adults or newborns. The most common condition was Guillain-Barré syndrome, with microcephaly being the most serious as a result of prenatal infection.

**DESCRIPTORS:** Epidemiology. Hospital Procedures. Cervical Cancer. Time Analysis.

### RESUMEN

Objetivo: Determinar las principales manifestaciones neurológicas resultantes de la infección humana por el virus Zika. Metodología: Revisión sistemática de artículos publicados en Science Direct y Scielo, con el siguiente algoritmo de búsqueda: Zika virus and neurological manifestations and diseases of the nervous system. Se incluyeron los estudios epidemiológicos que informaban de trastornos neurológicos relacionados con la infección por el virus Zika. Se excluyeron los estudios con animales y las revisiones sistemáticas. Los datos fueron extraídos y revisados por 3 investigadores, que acordaron los artículos seleccionados. Resultados: En esta revisión se seleccionaron 26 artículos, que revelaron como principales alteraciones el síndrome de Guillain-Barré, microcefalia, encefalitis, meningoencefalitis, mielitis, parálisis facial, cambios congénitos, cambios oculares, así como cambios radiológicos y electroencefalográficos. Conclusión: La infección por el virus Zika ha causado una serie de alteraciones neurológicas en la población infectada, ya sean adultos o recién nacidos. La afección más frecuente fue el síndrome de Guillain-Barré, siendo la microcefalia la más grave como consecuencia de la infección prenatal.

**DESCRIPTORES:** Virus Zika; Manifestaciones neurológicas, Enfermedades del sistema nervioso.

RECEBIDO EM: 26/05/2023 APROVADO EM: 18/07/2023

**How cited:** Sales FPOA, Filho JOS, Monteiro DLS. Zika vírus and neurological manifestation: a systematic review. Saúde Coletiva (Edição Brasileira) [Internet]. 2024 [acesso ano mês dia];14(89):13166-13179. Disponível em:  
DOI: 10.36489/saudecoletiva.2024v14i89p13166-13179

**ID Francisco Pedro Olimpio de Albuquerque Sales**

Programa de Pós-Graduação em Ciências Médicas, Centro Universitário INTA - UNINTA, Sobral, Ceará, Brasil. Residente de Clínica Médica da Santa Casa de Misericórdia de Sobral/Universidade Federal do Ceará.  
ORCID: 0009-0004-6535-7550

**ID João Oliveira e Silva Filho**

Programa de Pós-Graduação em Ciências Médicas, Centro Universitário INTA - UNINTA, Sobral, Ceará, Brasil. Residente em Terapia Intensiva do Hospital UDI Do'r São Luís.  
ORCID: 0009-0001-6564-4478

**ID Diego Levi Silveira Monteiro**

Programa de Pós-Graduação em Ciências Médicas, Universidade Federal do Ceará, Fortaleza, Ceará, Brasil. Professor do Curso de Medicina da Universidade Federal do Ceará, Sobral, Ceará, Brasil.  
ORCID: 0000-0002-4964-0493

**INTRODUCTION**

The Zika virus (ZIKV), a flavivirus transmitted by a mosquito with the same disease as the cause of yellow fever and dengue virus, is a major outbreak in the Americas<sup>(1)</sup>. This flavivirus was first isolated in 1947 from the blood of a monkey sentinel rye (*Macaca mulatta*) in the Zika forest near Entebbe, Uganda<sup>(2)</sup>.

Zika fever is an exanthematic disease characterized by symptoms that can last 1 week, with a clinical presentation similar to other arboviral infections such as chikungunya and dengue, including mild fever, rash, arthralgia, arthritis, myalgia, headache, conjunctivitis and edema. Severe cases involving hospitalization are uncommon, and deaths are rare<sup>(2)</sup>.

In May 2015, the World Health Organization reported the first locally acquired transmission of ZIKV in Brazil, the first case in the Western Hemisphere<sup>(3)</sup>. The Brazilian Ministry of Health, in November 2015, declared a public health emergency in relation to the abnormal increase of children born with microcephaly in this period, in the state of Pernambuco<sup>(4)</sup>. There have also been reports of increased incidences of other neurological complications, as well as an increase of 20 incidence of Guillain-Barre syndrome during outbreaks<sup>(3,6)</sup>.

This correlation of neurological symptoms with Zika virus infection, stating that unlike most viruses, this mainly affects the human nervous system, resul-

ting in fetal microcephaly, ocular disease and Guillain-Barré syndrome<sup>(7)</sup>.

The challenge with relationship to Zika virus infection is not only in controlling the disease, but also in the potential sequels of congenital infection and neurological complications<sup>(10)</sup>. Therefore, due to the paucity of studies that orderly group the neurological complications of higher or lower degree associated to this virus. For this reason, this systematic review aims to determine the main neurological manifestations resulting from human infection with the Zika virus.

**METHODS**

A systematic review was made of the medical literature that consisted of searching for articles on the neurological manifestations caused by the Zika virus. The searches were carried out in the databases of the scientific literature Science Direct and Scielo. These databases were chosen because they ensure a broad search of existing articles on the topic in question in current literatures. The review was carried out using the following search algorithm: "Zika virus" and "Neurological manifestations" and "Diseases of the nervous system". The following filters were used: human studies, since this review only evaluated the virus's repercussion in the human organism after infection, revealing more reliable data than in other animal organisms; between 2008 and 2018, since there was greater

epidemiological repercussion due to the outbreaks in the Brazilian territory. There were no language restrictions when choosing articles. After reading the titles and abstracts were observed epidemiological studies that reported neurological disorders related to Zika virus infections. The exclusion criteria were: systematic reviews, studies that do not directly address the topic addressed and animal research. Three reviewers (F.P.O.A.S., D.L.S.M. and J.O.S.F.) independently assessed the articles, seeking to examine eligibility through meetings to confirm the choice of studies. In cases of disagreement regarding the articles selected, discussions were held on the relevance of the theme and coherence with the objectives of the research until a common agreement among the reviewers.

The PRISMA11 guideline (Main Items for Systematic Review Reports and Meta-analyzes) on systematic reviews explains the importance of distinguishing quality and risk from bias and maintaining focus on evaluation and reporting the latter to undertaking a systematic review. However, in the review worked here, the objective was only in the identification and consolidation of neurological manifestations. Thus, the main objective of the analysis of the studies was to evaluate their quality or risk of bias.

Data extraction was performed independently by three reviewers (F.P.O.A.S., D.L.S.M. and J.O.S.F.) through frequent meetings, seeking to ensure that all

# Revisão Sistemática EN

Francisco P.O.A. Sales, João O.S. Filho, Diego L.S. Monteiro  
Zika vírus and neurological manifestation: a systematic review

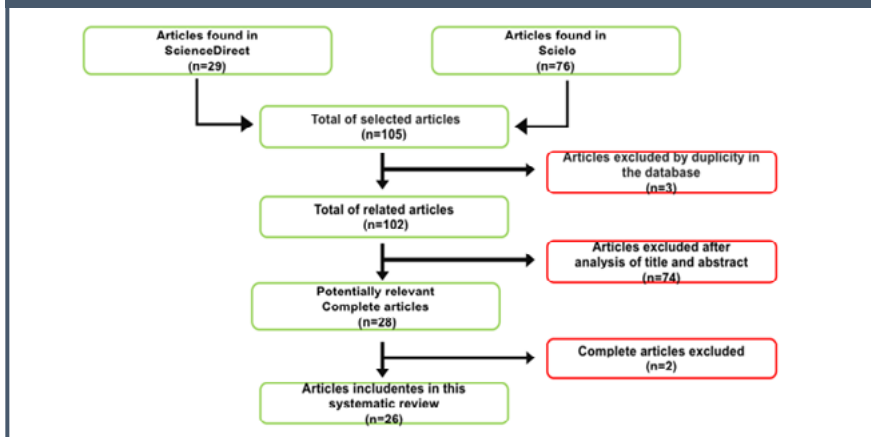
appropriate data were collected. A table (annex-1) was also prepared for the organization of the data of the articles, containing the following items: authors, title, year, type of study, information about the neurological symptoms reported in the study and justification for inclusion in the study.

## RESULTS

Following the search mechanisms, 29 articles were found in the databases of ScienceDirect and 76 articles in Scielo, of which, 3 were initially excluded, since they were present in the two databases, leaving 102 articles in total. Then, these articles were submitted to a first screening, which took into account the reading of titles and abstracts. In this first screening were selected the articles seen as potentially relevant to the data collection. After the screening, 74 articles were excluded and 28 were selected. Those 28 selected went through a second screening, which took into consideration the complete reading of the articles. After that, 2 more articles were excluded because they did not report neurological manifestations and 26 were selected for review.

A study proposed to show the epidemiological and clinical characteristics of the Zika virus infection in a descriptive study in which Guillain-Barré

Figure 1: organization chart of the bibliographic review research. Sobral, Ceará, Brazil, 2023



Source: Francisco Pedro Olimpio de Albuquerque Sales

syndrome and Microcephaly were the main neurological manifestations of this infection<sup>(12)</sup>.

A multicentric and prospective research, that 47 patients presented manifestations of Guillain-Barré syndrome and 2 patients evolved with symptoms characteristic of encephalitis. To do so, he followed a series of 49 cases of critically ill adult patients with laboratory diagnosis of ZIKV in 16 ICUs from 8 countries<sup>(13)</sup>.

Already in a case-control study, evaluated the possible association between ZIKV infection and Guillain-Barré syndrome during an outbreak in Bar-

ranquilla, Colombia, between 2015 and 2016, besides showing the association with cases of facial paralysis<sup>(14)</sup>.

In another study, pregnant women with ZIKV it has a positive association between microcephaly and other structural changes, such as calcifications, corpus callosum abnormalities, cortical malformations, and ventriculomegaly with Zika's viral infection<sup>(15)</sup>.

In table 1 presents the results of the main neurological manifestations discussed here in comparison with other equivalent reviews of current literature review of neurological manifestations as a result of Zika virus infection.

Table 1: scientific papers revealing neurological changes post infection by Zika virus. Sobral, Ceará, Brazil, 2023

AUTHORS	ARTICLE	NEUROLOGICAL MANIFESTATIONS
Casale <sup>12</sup>	Zika virus: An emerging infectious disease with serious perinatal and neurologic complications	Guillain-Barré syndrome; Microcephaly.
Sebastião <sup>13</sup>	Zika virus-induced neurological critical illness in Latin America: Severe Guillain-Barre Syndrome and encephalitis.	Guillain-Barré syndrome; Encephalitis.
Salinas <sup>14</sup>	Zika virus disease-associated Guillain-Barré syndrome—Barranquilla, Colômbia 2015–2016.	Guillain-Barré syndrome; Hyporeflexia; Lower or upper extremity weakness; Facial weakness; Inflammatory demyelinating polyneuropathy(AIDP); Acute motor axonal neuropathy(AMAN)..

Sanz Cortes <sup>15</sup>	Clinical Assessment and Brain Findings in a Cohort of Mothers, Fetuses and Infants Infected with Zika Virus.	Microcephaly; Brain volume loss; Calcifications; Callosal anomalies; Cortical malformations; Ventriculomegaly; Brain microcalcifications.
Chang <sup>16</sup>	The Zika outbreak of the 21st century.	Brain damage; Guillain-Barré syndrome; Microcephaly.
Anaya <sup>17</sup>	A comprehensive analysis and immunobiology of autoimmune neurological syndromes during the Zika virus outbreak in Cúcuta, Colômbia.	Guillain-Barré syndrome; Transverse myelitis; Encephalitis; Peripheral facial palsy; Thoracolumbosacral myelopathy.
Carvalho <sup>18</sup>	Sleep EEG patterns in infants with congenital Zika vírus syndrome.	Microcephaly; Hypsarrhythmia; Interictal epileptogenic activity; Background asymmetry.
Salinas <sup>19</sup>	Incidence and clinical characteristics of Guillain-Barré syndrome before the introduction of Zika virus in Puerto Rico.	Guillain-Barré syndrome; Polyneuropathy.
Linden <sup>20</sup>	Discordant clinical outcomes of congenital Zika virus infection in twin pregnancies.	Microcephaly; Ventriculomegaly; Calcifications; Hypoplasia.
Peixoto <sup>21</sup>	Computed tomography and magnetic resonance imaging findings in infants with microcephaly potentially related to congenital Zika virus infection.	Microcephaly; Calcifications; Ventriculomegaly; Posterior fossa alterations; Malformations of cortical development; Lissencephaly; Polymicrogyria; Colpocephaly; Hemisphere hypoplasia.
Ribeiro <sup>22</sup>	Microcephaly in Piauí, Brazil: a descriptive study during a Zika virus epidemic, 2015-2016.	Microcephaly; Calcifications; Brain atrophies; Lysencephaly; Ventriculomegaly; Digenesia.
Castro <sup>23</sup>	Presumed Zika virus-related congenital brain malformations: the spectrum of CT and MRI findings in fetuses and newborns.	Microcephaly; Ventriculomegaly; Reduction of white matter thickness; Severe Sylvian fissure simplification; Abnormal sulcation; Diffuse volumetric loss of cerebellar hemispheres; Cerebellar hypoplasia; Enlarged cisterna magna.
Cabral <sup>24</sup>	Clinical-epidemiological description of live births with microcephaly in the state of Sergipe, 2015.	Microcephaly; Agenesis of corpus callosum; ysencephaly; Absence of midline; Ventriculomegaly; Headache.
Nascimento <sup>25</sup>	Teratogens: a public health issue – a Brazilian overview.	Microcephaly; Intellectual disability; General developmental delay; Intellectual disabilities; Cognitive impairment; Attention deficit/hyperactivity; Autism.
Malta <sup>26</sup>	Guillain-Barré syndrome and other neurological manifestations possibly related to Zika virus infection in municipalities of Bahia, 2015.	Guillain-Barré syndrome.
Coronell-Rodríguez <sup>27</sup>	Infección por virus del Zika en el embarazo, impacto fetal y neonatal.	Microcephaly; Congenital syndrome of zika;
Vargas <sup>28</sup>	Characteristics of the first cases of microcephaly possibly related to the Zika virus reported in the Metropolitan Region of Recife, Pernambuco.	Microcephaly; Cerebral calcifications; Ventriculomegaly; Lissencephaly.

# Revisão Sistemática EN

Francisco P.O.A. Sales, João O.S. Filho, Diego L.S. Monteiro  
Zika vírus and neurological manifestation: a systematic review

Ventura <sup>29</sup>	Ophthalmological findings in infants with microcephaly and presumable intra-uterus Zika virus infection.	Cerebral calcifications; Microcephaly; Nystagmus; Macular retinal changes; Hypoplasia of the optic nerve; Exophoria; Chorioretinal atrophy; Foveal reflex loss.
Alves <sup>30</sup>	Epileptic seizures in children with congenital Zika virus syndrome.	Epileptic seizure; Spasms; Generalized tonic seizures.
Souza <sup>31</sup>	Altered intrauterine ultrasound, fetal head circumference growth and neonatal outcomes among suspected cases of congenital Zika syndrome in Brazil.	Microcephaly.
Pinheiro <sup>32</sup>	Neurological manifestations of Chikungunya and Zika infections.	Meningo-encephalitis; Meningoencephalomyelitis; Myeloneuropathy; Guillain-Barré syndrome.
Albinagorta <sup>33</sup>	Fetal health and ultrasonographic diagnosis in perinatal infection due to Zika virus.	Microcephaly; Ventriculomegaly; Periventricular and intraparenchymal calcifications; Agenesis or dysgenesis of the corpus callosum; Alterations of cortical development; Brain atrophy; Alterations of the cerebellum and brainstem; Ocular abnormalities; Congenital syndrome of Zika.
Zoghbi <sup>34</sup>	The arrival of Zika virus to Venezuela and its possible footprint in mother-child health. An unmatched discussion.	Microcephaly; Epilepsy; Cerebral palsy; Mental retardation.
Brito <sup>35</sup>	Zika in Pernambuco: rewriting the first outbreak.	Microcephaly.
Aspilcueta-Gho <sup>36</sup>	Zika virus infection in Peru: from threat to a health problem.	Guillain-Barré syndrome; Microcephaly.
Perret <sup>37</sup>	Zika virus, guilty or innocent?	Guillain-Barré syndrome; Microcephaly; Meningoencephalitis.

## DISCUSSION

Different neurological manifestations were identified in association with the Zika virus in this literature review, such as: Guillain-Barré syndrome, Microcephaly, encephalitis, meningoencephalitis, myelitis, facial paralysis, congenital alterations, ocular alterations, radiological and electroencephalographic alterations, etc. among other manifestations that are usually forgotten. Evidence has shown that Guillain-Barré syndrome and microcephaly are the most frequently reported manifestations in the literature, leading us to infer that these are the most prevalent manifestations to date.

Corroborating with this observation

about the increasing index of microcephaly, a review showed the main epidemiological characteristics and atypical manifestations, mainly neurological, that although the incidence between Zika virus and pregnant is not well known, microcephaly increased more than 20 times in newborns after outbreaks of Zika virus infection<sup>(2)</sup>.

Guillain-Barré syndrome has in recent years been one of the most correlated neurological manifestations with ZIKV infection. In this review, 10 articles were found in which this correlation was found. However, according to another study, the pathophysiological causality between ZIKV and GBS infection has not yet been proven and a possible

mechanism can only be hypothesized<sup>(1)</sup>.

Among other neurological complications other than those most prevalent, a study correlates ZIKV infection with the development of encephalitis, meningoencephalitis, facial paralysis and myelitis<sup>(4)</sup>. These findings corroborate this review as evidencing the possibility of developing other neurological disorders other than those normally related to this infection, such as microcephaly and Guillain-Barré.

Going further as to the demonstration of the variety of neurological manifestations provoked by the Zika virus, a research reveals ocular manifestations resulting from this infection, in which they have been more frequent and more and

more well described as in the congenital ocular syndrome resulting from Zika. This may be due to the steady expansion in arbovirus epidemics, and partly due to climate change and globalization, where it has occurred more frequently even in Europe<sup>(38)</sup>. These ophthalmic changes are also cited in this review, and despite increasing studies on this change, it is still an unexplored manifestation in relation to other neurological changes caused by the Zika virus.

Analyzing the changes caused by the Zika virus from another perspective, an article reported that neuroimaging findings in the congenital syndrome by ZIKV are not pathognomonic, but the diagnosis can be suggested when associated with compatible clinical data present. The craniofacial disproportion with microcephalic aspect associated with calcifications predominating in the cortical-subcortical junction are the main radiological findings in this syndrome<sup>(39)</sup>. These image data showing calcifications in the CNS corroborate with the present results in this research, which reports, among other alterations, findings of cranioencephalic calcification present in the fetuses when searched around the fifth month of gestation.

Concomitant with this imaging evaluation, another article reports the importance of imaging exams in associa-

tion with laboratories during gestation, in order to diagnose the early neurological changes in pregnant women infected with Zika virus. Because these changes are usually found in fetal brain tissue in a reverse transcriptase polymerase chain reaction (RT-PCR) assay, with consistent findings in electron microscopy<sup>(40)</sup>. Thus, the search for complementary exams that show alterations in less specific neurological findings, such as hydrocephalus and multifocal dystrophic calcifications in the cortex and subcortical white matter, associated cortical displacement and moderate focal inflammation may be very useful in preventing further complications due to this.

At the end of this summation of literary information and scientific evidence regarding the correlation of the Zika virus and the neurological manifestations resulting from its infection, there is still a limitation to explain the pathophysiological mechanism of viral action on nervous tissue, despite the already documented manifestations.

In summary, the relevance of all the information contained in the research is highlighted by bringing to the reader's knowledge the various neurological manifestations associated with zika virus infection, often not known by most health professionals due to the lack of further research and reading in the area. Studies

in this field are still focused on reporting the most serious or most prevalent manifestations of the disease, leaving a gap to be filled in on the other, no less important, changes caused by this arbovirus.

## CONCLUSION

From the literature review of this review we can conclude that Guillain-Barre syndrome and microcephaly are the neurological manifestations most correlated with Zika virus infection in current literature. Thus, in terms of citations, we can infer that they are the most prevalent and described, but, other enumerations alterations, not less important also occur. The knowledge of the vast modification caused in the nervous system by the viral infection of the Zika, suggests the adoption of early therapeutic interventions and allows new prognosis regarding the disease. In addition to reinforcing the need for the adoption of prophylactic measures against the numerous functional and organic losses caused in the human organism.

## REFERENCES

- Goeijenbier M, Slobbe L, Van der Eijk A, Melo M, Koopmans M, Reusken C. O vírus Zika e o surto atual: uma visão geral. *The Nether J of Med* 2016;74(3):104-9. doi: 10.1016/j.njmed.2016.03.001.
- Paixão ES, Barreto F, Rodrigues LC. Histórico, Epidemiologia e Manifestações Clínicas do Zika: Uma Revisão Sistemática. *American J of P Health* 2016;106(4):606-12. doi: 10.2105/AJPH.2016.303112.
- Richmond D, Mashburn MP, Jessica L. Doença pelo vírus Zika: Relato de caso e revisão da literatura. *Pediatric E Care* 2016;32(10):705-9. doi:10.1097/PEC.0000000000000932.
- Pinheiro TJ, Guimarães LF, Silva MT, Soares CN. Manifestações neurológicas das infecções por Chikungunya e Zika. *View e Review* 2016;10.1590:937-43.937. doi: 10.1590/0004-282X20160138.
- Brasil. Ministério da Saúde. Ministério da Saúde declara emergência na saúde pública do país. *Jornal Estado de Minas* 2015 Nov. Postado 11/11/15 às 18:49.6. Brito CA, et al. Zika em Pernambuco: reescrevendo o primeiro surto. *Rev Soc Bras Med Trop* 2016;49(5):553-58. doi: 10.1590/0037-8682-0245-2016.
- Silasi, M. et al. Viral infections during pregnancy (Infecções virais durante a gravidez). *Am. J.Reprod. Immunol* 2015;73:199-213. doi:10.1111/aji.12355.
- Barouch DH, Thomas SJ, Michael NL. Perspectivas para uma vacina contra o vírus Zika. *Immunity* 2017;46(2):176-82. doi: 10.1016/j.immuni.2017.02.005.
- Mota Oliveira MT, Terzian AC, Rodrigues Silva ML, Estofolete C, Nogueira ML. Vírus transmitidos por mosquitos - o grande desafio brasileiro. *Brazilian J of Micro* 2016;47(1):48-50. doi: 10.1016/j.bjm.2016.10.008.
- Levin SN, Lyons J. Infections of the Nervous System (Infecções do sistema nervoso). *The Amer J of Med* 2017 Sep. *American J of P Health* 2016;106(4):606-12. doi: 10.1016/j.amjmed.2017.08.020.
- Song Sai-Yin S, Poon Wing-Shan R, Wong Cheuk-Ying S. Zika virus infection-the next wave after dengue? *Journal of the F Med Ass* 2016;115(4):226-42. doi: 10.1016/j.jfma.2016.02.002.

11. Galvão TF, Pansani TS, Harrad D. Principais itens para relatar Revisões sistemáticas e Meta-análises: A recomendação PRISMA. *Epidemiol Serv Saúde* 2015;24(2):335-42. doi: 10.5123/S1679-49742015000200017.
12. Casele T.B.; Teng M.N.; Morano J.P.; Unnasch T.; Lockwood C.J., Zika virus: An emerging infectious disease with serious perinatal and neurological complications (Uma doença infecciosa emergente com complicações perinatais e neurológicas graves). *J Allergy Clin Immunol*. 2018 fev; 141 (2): 482-490. doi: 10.1016/j.jaci.2017.11.02.
13. Sebastião UU, Ricardo AVA, Alvarez BC, Cubides A, Luna AF, Arroyo-Parejo M et al. Doença neurológica crítica induzida pelo vírus Zika na América Latina: Síndrome de Guillain-Barré grave e encefalite. *Journal of critical care* 2017 Dec; 42:275-281. doi: 10.1016/j.jccr.2017.07.038.
14. Salinas JL, Walteros DM, Styczynski A, Garzón F, Quijada H, Bravo E et al. Zika virus disease-associated Guillain-Barré syndrome-Barranquilla, Colômbia 2015-2016. *J Neurol Sci*. 2017 Oct 15;381:272-277. doi: 10.1016/j.jns.2017.09.001.
15. Sanz Cortes M, Rivera AM, Yopez M, Guimaraes CV, Diaz Yunes I, Zarutskie A et al. Clinical assessment and brain findings in a cohort of mothers, fetuses and infants infected with ZIKA virus. *Am J Obstet Gynecol*. 2018 Apr; 218 (4): 440 e 1- 440 e 36. doi: 10.1016/j.ajog.2018.01.012.
16. Chang C; Ortiz K; Ansari A; Gershwin ME. The Zika outbreak of the 21st century (O surto de Zika no século 21). *J Autoimmun*. 2016 Apr;68:1-13. doi: 10.1016/j.jaut.2016.02.006.
17. Anaya JM, Rodríguez Y, Monsalve DM, Vega D, Ojeda E, González-Bravo D et al. A comprehensive analysis and immunobiology of autoimmune neurological syndromes during the Zika virus outbreak in Cúcuta, Colômbia. *J Autoimmun*. 2017 Feb;77:123-138. doi: 10.1016/j.jaut.2016.12.007.
18. Carvalho MDCG, Miranda-Filho DB, van der Linden V, Sobral PF, Ramos RCF, Rocha M W, et al. Sleep EEG patterns in infants with congenital Zika vírus syndrome. *Clin Neurophysiol*. 2017 Jan;128(1):204-214. doi: 10.1016/j.clinph.2016.11.004.
19. Salinas JL, Major CG, Pastula DM, Dirlikov E, Styczynski A, Luciano CA et al. Incidence and clinical characteristics of Guillain-Barré syndrome before the introduction of Zika virus in Puerto Rico. *J Neurol Sci*. 2017 Jun 15;377:102-106. doi: 10.1016/j.jns.2017.04.006.
20. Linden VV, Linden HV Junior, Leal MC, Rolim EL Filho, Linden AV, Aragão MFV et al. Resultados clínicos discordantes da infecção congênita pelo vírus Zika em gestações gemelares. *Arq Neuropsiquiatr*. 2017 Jun;75(6):381-386. doi: 10.1590/0004-282X20170006.
21. Peixoto AA, Freitas SB, Ciosaki MM, Nogueira L, Santos OT. Achados de tomografia computadorizada e ressonância magnética em bebês com microcefalia potencialmente relacionada à infecção congênita pelo vírus Zika. *Radiol Bras*. 2018 Mar-Abr;51(2):119-122. doi: 10.1590/0100-3984.2016.0135.
22. Ribeiro IG, Andrade MR, Silva JM, Silva ZM, Costa MAO, Vieira MADCES et al. Microcefalia no Piauí, Brasil: estudo descritivo durante a epidemia do vírus Zika, 2015-2016. *Epidemiol Serv Saude*. 2018 Feb 1;27(1). doi: 10.5123/S1679-49742018000100002.
23. Castro JDV, Pereira LP, Dias DA, Aguiar LB, Maia JCN, Costa JIFD et al. Presumíveis malformações cerebrais congênitas relacionadas ao vírus Zika: o espectro de achados de TC e RM em fetos e recém-nascidos. *Arq Neuropsiquiatr*. 2017 Oct;75(10):703-710. doi: 10.1590/0004-282X20170134.
24. Cabral CM, Nóbrega MEBD, Leite PLE, Souza MSF, Teixeira DCP, Cavalcante TF et al. Descrição clínico-epidemiológica dos nascidos vivos com microcefalia no estado de Sergipe, 2015. *Epidemiol Serv Saude*. 2017 Abr-Jun;26(2):245-254. doi: 10.5123/S1679-49742017000200002.
25. Nascimento TM, Melo DG, Morbioli GG, Carrilho E, Vianna FS, Silva AA. Teratógenos: uma questão de saúde pública - um panorama brasileiro. *Genet Mol Biol*. 2017 Apr-Jun;40(2):387-397. doi: 10.1590/1678-4685-GMB-2016-0179.
26. Malta JAMS, Vargas A, Leite PL, Percio J, Coelho JE, Ferraro AHA et al. Síndrome de Guillain-Barré e outras manifestações neurológicas possivelmente relacionadas à infecção pelo vírus Zika em municípios da Bahia, 2015. *Epidemiol. Serv. Saúde*, Brasília, 26(1), jan-mar 2017. doi: 10.5123/s1679-49742017000100002.
27. Coronell-Rodríguez W, Arteta-Acosta C, Suárez-Fuentes MA, Burgos-Rolon MC, Rubio-Sotomayor MT, Sarmiento-Gutiérrez M. et al. Zika virus infection in pregnancy, fetal and neonatal impact. *Rev Chilena Infectol* 2016; 33 (6): 665-673. doi: 10.4067/S0716-10182016000600009.
28. Vargas A, Saad E, Dimech GA, Santos RH, Sivini MAVC, Albuquerque LC et al. Características dos primeiros casos de microcefalia possivelmente relacionados ao vírus Zika registrados na Região Metropolitana de Recife, Pernambuco. *Epidemiol. Serv. Saúde*, Brasília, 25(4), out-dez 2016. doi: 10.5123/s1679-49742016000400003.
29. Ventura CV, Maia M, Ventura BV, Linden VV, Araújo EB, Ramos RC et al. Achados oftalmológicos em bebês com microcefalia e presumível infecção intra-uterina pelo vírus Zika. *Arq Bras Oftalmol*. 2016;79(1):1-3. doi: 10.5935/0004-2749.20160002.
30. Alves LV, Cruz DDCS, Linden AMCV, Falbo AR, Mello MJG, Paredes CE et al. Crises epilêpticas em crianças com síndrome congênita do vírus Zika. *Rev. Bras. Saúde Matern. Infant., Recife*, 16 (Supl. 1): S27-S31 nov., 2016. doi: 10.1590/1806-9304201600s100003.
31. Souza ASR, Souza AI, Faquin SLL, Neto OGS, Honorato E, Mattos AGL et al. Alterações na ultrassonografia intrauterina, no crescimento do perímetro cefálico fetal e nos resultados neonatais entre casos suspeitos de síndrome congênita do Zika no Brasil. *Rev. Bras. Saúde Matern. Infant., Recife*, 16 (Supl. 1): S7-S15 nov., 2016. doi: 10.1590/1806-9304201600s100002.
32. Pinheiro TJ, Guimarães LF, Silva, MT, Soares, CN. Manifestações neurológicas das infecções por Chikungunya e Zika. *Arq Neuropsiquiatr* 2016;74(11):937-943. doi: 10.1590/0004-282x20160138.
33. Albinagorta RO, Díaz-Vela, MP. Saúde fetal e diagnóstico ultrassonográfico na infecção perinatal devido ao vírus Zika. *Journal of Medical Ultrasound (Revista de Ultrassom Médico)*. Volume 24, Edição 3, Setembro de 2016, Páginas 89-92. doi: S2304-51322017000100009.
34. Zoghbi N, López, A. The arrival of Zika virus to Venezuela and its possible footprint in mother-child health. Uma discussão inigualável. *Epidemiologia en Acción*. Jul 2016; 14 (1): 67-73.
35. Brito CAA, Brito CCM, Oliveira AC, Rocha M, Atanásio C, Asfora C et al. Zika em Pernambuco: reescrevendo o primeiro surto. *Rev. Soc. Bras. Med. Trop.* vol.49 no.5 Uberaba Sept./Out. 2016. doi: 10.1590/0037-8682-0245-2016.
36. Aspilcueta-Gho D, Villafane CB, Menel M, Sánchez C, Yberico JGC. Zika infection in Peru: from threat to health problem (Infecção por zika no Peru: de ameaça a problema de saúde). *Rev. peru. ginecol. obstet.* vol.63 no.1 Lima Jan./Mar. 2017. pid: S2304-51322017000100007
37. Perret C. Zika virus, guilty or innocent? *Rev. chil. infectol.* vol.33 no.2 Santiago Apr. 2016. doi: 10.4067/S0716-10182016000200008.
38. Merle H, Donnio A, Jean-Charles A, Guyomarch J, Hage R, Najjoulah F et al. Ocular manifestations of emerging arboviruses: Dengue, Chikungunya, vírus Zika, vírus do Nilo Ocidental e febre amarela. Volume 41, Edição 6, Junho de 2018, Páginas e 235 - e 243. doi: 10.1016/j.jfo.2018.05.002
39. Ribeiro BNF, Muniz BC, Gasparetto EL, Ventura N, Marchiori E. Congenital Zika syndrome and neuroimaging findings: what do we know so far? *Radiol Bras*. 2017 Set/Out;50(5):314-322. doi: 10.1590/0100-3984.2017.0098.
40. Mlakar J, Korva S, Tul N, Popovic M, Poljsak-Prijatelj M, Mraz J et al. Zika Virus Associated with Microcephaly. *N Engl J Med* 2016; 374:951-958. doi: 10.1056/NEJMoa1600651.